

Appendix XI

Emergency partial pulpectomy

Authors: Peter Omejc, Mojca Harej, Pavel Kvapil


Reviewers: Ana Nemeč

Emergency partial pulpectomy is ideally performed in fractured teeth with pulp exposed less than 48 hours (data from dogs). The success of the procedure is 80% in this case and drops greatly in older fractures, necessitating extraction or total pulpectomy.



DENTAL REPAIR KIT: 1. Portable electric grinder with different grinding heads, 2. Blowing pump, 3. Swabs, 4. Absorbent paper points, 5. Dental cement, 6. Glass tray for cement preparation, 7. Dental probes (with blunt points), 8. Selfedge, 9. UV light, 10. Composite applicator

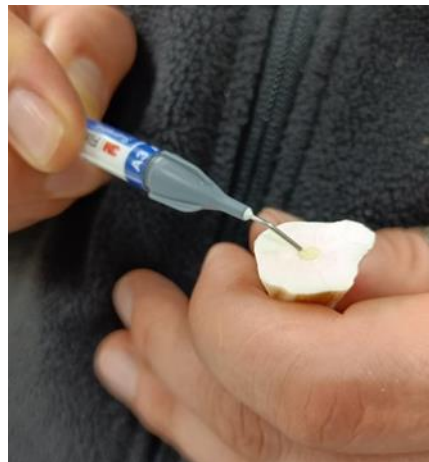1. Gently wipe the surface of the tooth with medical-grade bleach (0,5%) and remove any sharp dental edges.
2. If fracture is peracute, stop the bleeding by placing a sterile paper point into the pulp cavity (not deeper than 5 mm); if fracture is older (but < 48 hours), coronal 5 mm of the infected pulp have to be removed with a sterile bur.
3. Preparing MTA to a sticky consistency-4 drops of NaCl (0,9%) in semi-circular position around dental cement; mixing till the mixture is solid but still shapable.



4. Gently place 1 mm layer onto the pulp, using blunt-ended tip of the sterile paper point.



5. Cleaning the upper edges (at least 2 mm) of the tooth's fracture with sterile cotton swabs or (once MTA is set) with a spoon excavator, so there is no dental cement left on the walls of the cavity (just over the pulp).
6. Putting drops of Self etch on top of MTA and around the upper edges of the wound
7. Light-cure for 15 seconds (or as per manufacturer's instructions).
8. Administering (flowable) composite (Flowable restorative, Filtek) on top of the Self etch layer.



9. Light-cure for 15 seconds under UV light, repeat 3 times. (or as per manufacturer's instructions).
10. If necessary, repeat Composit layer and UV lightning (suggested for better solidity).
11. Smooth the Composit layer until levelled with toot's surface.